

A Simple Technique for Fabrication of Immediate Interim Removable Prosthesis Supported by Transitional Implants

David Leshem, MD,* Ziv Mazor, DMD,** Roy Leshem, DMD,*** Daren Rosen, DDS†

Integration of implants into the jaw is dependent on the initial stability of the implants. Most surgeons prefer to wait several months for the healing process to take place before constructing the prosthesis for the implant(s).¹ Recently, as a result of clinical research, progressive shortening of the healing period is recommended and immediate implant loading is being performed in select cases.²⁻⁵ However, it should be remembered that the success of immediate-loaded implants is highly dependent on the initial bone density at the implant site and the meticulous occlusal force equilibration,⁶ and that even minor movement of implants during the osseointegration period can interfere with the healing process, causing fibrosis around the implant and accelerated crestal resorption.^{7,8} In the unfortunate event that a single implant fails after immediate restoration of several fixtures, the entire prosthesis may have to be replaced. Therefore, loading of final implants is often delayed.^{7,9-11}

In an effort to eliminate the forces placed on the implants and the surgical site by the existing denture immediately after surgery, patients are often requested to refrain from wearing their dentures for at least 7 days after stage 1 surgery. Furthermore, trauma to the soft tissue over the fixtures should be avoided to decrease the possibility of

The healing period between implant insertion and exposure is often challenging for both the patient and the surgeon. The use of a removable dental prosthesis is not recommended for a period of several days to 2 weeks in an effort to avoid undue pressure being placed on the newly placed implants and on the surrounding soft tissues. However, patients are frequently uneasy without dentures, even for a short period of time, because their diet and appearance are compromised. A simple technique was developed to overcome these obstacles. This technique allows the surgeon to place an im-

incision dehiscence. However, most patients refuse to remain without dentures even for a short period. A transitional implant was developed to meet the patient's need to wear a denture during the healing period and to meet the surgeon's request to protect the implant site by avoiding any prosthetic trauma to the implant area.

The purpose of this article is to describe a technique for simultaneous placement of transitional implants that enables patients to wear their prostheses immediately following surgery. These implants are designed to carry the load of the existing denture, thus relieving pressure on the soft tissue and the newly placed final implants. The transitional implant raises the prosthesis from the surgical site, thus avoiding trauma to the denture and the implants, and reduces the possibility of dehiscence of the incision. Immediate loading of transitional implants

mediate implant-supported prosthesis, based on two transitional implants, in addition to the implants placed for final restoration. This technique is performed at the surgical stage simultaneously with the placement of the permanent implants. It requires minimal additional time, and makes use of the patient's original prosthesis as an interim removable restoration during the integration period. (Implant Dent 2003;12:227-231)

Key Words: interim prosthesis, tissue preservation, immediate loading

does not entail any risk to the final restoration, and does not require fabricating a special interim restoration.

MATERIALS AND METHODS

Hi-Tec Implants Ltd. (Herzlia, Israel) designed and developed the TRI Transitional implant with a thread diameter of 2.4 mm and a thread length of 13 mm. The implant is produced from titanium grade V and designed with a 3-mm high smooth transgingival area and a square head with a ball attachment at its coronal end (Fig. 1). A total of 40 transitional implants were placed in the mandibles of 20 patients (8 men and 12 women) ranging in age from 60 to 75 years.

Surgery

Under local anesthesia, the implants for the final fixed or removable restoration were placed in the jaw as

*Chief Resident, Department of Plastic and Reconstructive Surgery, Sourasky Medical Center, Tel Aviv, Israel.

**Private Practice, Ra'anana, Israel.

***Private Practice, Herzlia, Israel.

†Senior Surgeon, Unit of Oral and Maxillofacial Surgery, Sapir Medical Center, Kfar Saba; Private Practice, Ra'anana, Israel.




Fig. 1. TRI-13 transitional implant.

predetermined by the treatment plan. During preparation of the implant sites, using a 2-mm internal irrigation drill, two additional sites were prepared in the jaw between the preparations for the final implants (Fig. 2). In type I bone, the bone was drilled to the depth of 12 mm, and in type II to the depth of 10 mm. Transitional implants were then inserted into the prepared sites using a ratchet until all threads were in the bone and the square head of the implant with the ball attachment extended supragingivally to support the prosthesis (Fig. 3). The incision was sutured in the customary manner (Fig. 4). Dentures were prepared by removing all of the acrylic above the surgical site to allow only the posterior portion of the denture to be in contact with the soft tissue. Cavities were then prepared in the denture base above the transitional implants and nylon caps were placed on the ball attachments. At this stage, proper seating of the denture was confirmed. Self-curing acrylic was applied to the inner denture portion above the ball attachments, which enabled the caps to bond

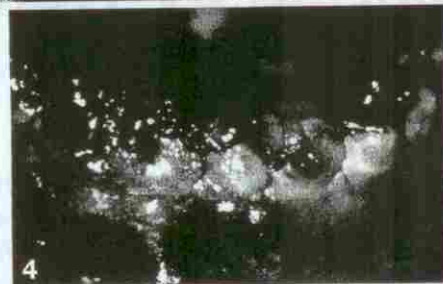
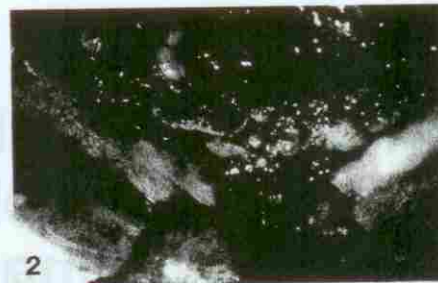


Fig. 2. Preparation for transitional implant between preparation for final implants.
 Fig. 3. TRI-13 placed in the mandible.
 Fig. 4. TRI-13 ball attachment extending supragingivally after suturing.

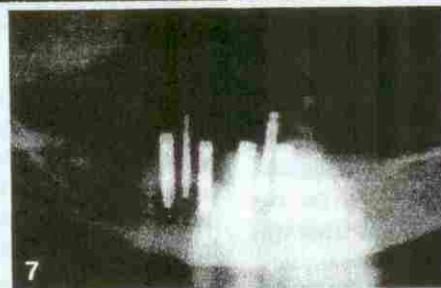
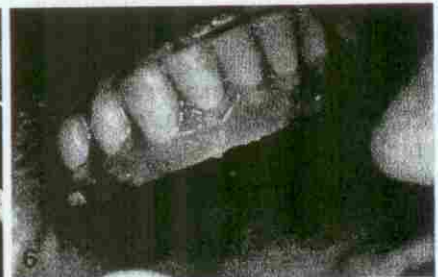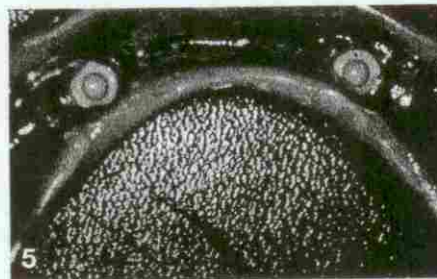


Fig. 5. Nylon caps bonded into the denture.
 Fig. 6. Denture seated on two TRI-13 without touching the gingiva at the surgical site.
 Fig. 7. Panoramic radiograph after 3 months.

with the denture. After the acrylic hardened, the denture was removed and trimmed to create a space between the prosthesis and the soft tissue at the surgical site (Figs. 5-7).

RESULTS

All 40 transitional implants remained stable and in function throughout the integration period. No signs of infection or implant mobility were noted. Radiographs taken at time of

exposure revealed no bone resorption apical to the second thread. All patients reported normal denture function and were satisfied with this interim restoration. No patient experienced any pain or discomfort.

DISCUSSION

Trauma caused by the immediate wearing of removable dentures after implant surgery can negatively affect osseointegration.¹² Furthermore,

trauma to the soft tissue can result in tension placed on the surgical incision. Subsequently, the tissue may dehiscence in that area. Many surgeons recommend that patients avoid wearing removable prostheses after implant surgery for at least 7 days. However, the patient often rejects this request because they may suffer eating difficulties and esthetic compromise in the absence of dentures.

The procedure described here offers the patient the advantage of dentures immediately after surgery. This is esthetically desirable, without impairing speech or mastication during the healing phase. Because the implants raise the denture above the height of the soft tissue crest, there is no danger of trauma to the gingival incision or of incurring dehiscence. Additionally, the final implants are protected from any possible occlusal forces, which would otherwise be transmitted from the denture to the bone. The use of the patient's original denture, without the need to fabricate a new one, enables the procedure to be completed during the surgical session, adding approximately 20 minutes to the surgery time. Of note was the fact that where bone loss was noted around the transitional implants, it was localized to the surroundings of the transitional fixture and did not, in any way, affect the survival of the adjacent implants.

Self-exposure of the buccal side of the implant due to the pressure applied by the denture during the integration period creates an esthetic compromise and loss of attached gingiva essential for soft tissue health around the implants. A TRI transitional implant supports the denture above the

soft tissue; therefore, the risk of self-exposure is minimized.

CONCLUSION

A dental prosthesis worn during implant osseointegration provides esthetic and functional advantages to the patient. Dentures supported by transitional implants avoid soft tissue trauma and protect fixed implants from any denture-generated occlusal forces that could compromise osseointegration. The technique described here allows the patient to wear the prosthesis immediately after surgery. The surgical site is protected from any undue forces that may be caused by the denture. This method is advantageous due to its simplicity. It requires only two transitional implants, uses the patient's existing denture, and is performed in a short period of time.

Disclosure

Two of the authors, Roy Leshem and David Leshem, have a financial interest in Hi-Tec Implants Ltd., whose product, TRI-13, is mentioned in this article. The other authors claim to have no financial interest in any company or product mentioned in this article.

REFERENCES

1. Wheeler SL. Eight-year clinical retrospective study of titanium plasma-sprayed and hydroxyapatite-coated cylinder implants. *Int J Oral Maxillofac Implants*. 1996; 11:340-350.
2. Ledermann PD. Der sofort-implantatOsteg im zahnlosen unterkiefer. *Swiss Dent*. 1996;17:5-18.
3. Spiekermann H, Jansen UK, Richter EJ. A 10-year follow-up study of IMZ and TPS implants in edentulous mandible us-

ing bar-retained overdentures. *Int J Oral Maxillofac Implants*. 1995;10:231-243.

4. Chiapasco M, Gatti C, Rossi E, et al. Implant-retained mandibular overdentures with immediate loading. A retrospective multicenter study on 226 consecutive cases. *Clin Oral Implants Res*. 1997;8:48-57.

5. Gatti C, Slid E, Rossi E, et al. Overdenture mandiboluri a esclusivo appoggio implantare e carico immediate. Studio prospettico su impianti Ha-Ti. *Implant Oral*. 1998;1:9-14.

6. Zubery Y, Bichiacho N, Moses O, et al. Immediate loading of modular transitional implants: A histomorphometric study in dogs. *Int J Periodontics Restorative Dent*. 1999;19:343-353.

7. Aspenberg P, Goodman S, Toksvig-Larsen S, et al. Intermittent micromotion inhibits bone ingrowth: Titanium implants in rabbits. *Acta Orthop Scand*. 1992;63: 141-145.

8. Lagawa Y, Ishikawa Y, Nikai H, et al. Interface histology of unloaded and early loaded partially stabilized zirconia endosseous implants in initial bone healing. *J Prosthet Dent*. 1993;69:599-607.

9. Meffert RM, Langer B, Fritz ME. Dental implants: A review. *J Periodontol*. 1992;63:859-870.

10. Uthoff HK. Mechanical factors influencing the holding power of screws in compact bone. *J Bone Joint Surg Br*. 1973;55:633-639.

11. Schtzecker J, Hoprne JG, Sumner-Smith G. The effect of movement on the holding power of screws in bone. *Clin Orthop*. 1975;111:257-262.

12. Piattelli A, Corigliano M, Scarano A, et al. Immediate loading of titanium plasma-sprayed implants: An histologic analysis in monkeys. *J Periodontol*. 1998; 69:321-327.

Reprint requests and correspondence to:

Roy Leshem, DMD

P.O. Box 2022

Herzlia, Israel

Phone: +072-9-955 8486

Fax: +972-9-958 6803

E-Mail: leshem_y@netvision.net.il



AUTOR(EN): David Leshem MD*, Ziv Mazor DMD**, Roy Leshem DMD***, Daren Rosen DDS****. *Leitender Assistenzarzt der Abteilung für Plastische und Wiederherstellungschirurgie, Medizinisches Zentrum Sourasky, Tel Aviv, Israel. **Privat praktizierender Arzt, Ra'anana, Israel. ***Privat praktizierender Arzt, Herzlia, Israel. ****Leitender Chirurg des Bereiches für Gesicht- und Kieferchirurgie, Medizinisches Zentrum Sapir, Kfar Saba; privat praktizierender Arzt, Ra'anana, Israel. Schriftverkehr: Roy Leshem, DMD, Postfach (P.O. Box) 2022, Herzlia, Israel. Telefon: +072-9-955-8486, Fax: +972-9-958-6803. eMail: leshem_y@netvision.net.il

Die Herstellung sofort einsetzbarer Interimsprothesen - eine einfache Technik unter Verwendung von Übergangsimplantaten

ZUSAMMENFASSUNG: Die Heilungsphase zwischen Implantateinsatz und letztendlicher Exposition stellt oftmals sowohl an den Patienten als auch an den behandelnden Chirurgen große Anforderungen. Nach Implantierung wird generell für mehrere Tage bis zu zwei Wochen von der Verwendung einer herausnehmbaren Prothese abgeraten. Dadurch soll verhindert werden, dass die frisch eingepflanzten Implantate und das umliegende Weichgewebe vorzeitig einer übermäßigen Belastung ausgesetzt werden. Allerdings verursacht diese vorübergehend auferlegte Zahnlosigkeit vielen Patienten Probleme, da sie sich sowohl bezüglich der Nahrungsaufnahme als auch vom Erscheinungsbild her beeinträchtigt fühlen. Es wurde daher eine einfach anzuwendende Technik entwickelt, um den sofortigen Einsatz einer vorübergehenden Prothese zu ermöglichen und damit die oben geschilderten Nachteile aus dem Weg zu räumen. Mittels dieser Methode kann der Zahnchirurg unmittelbar nach erfolgtem Eingriff eine implantatgestützte Prothese einsetzen, die an zwei Übergangsimplantaten befestigt ist. Diese Übergangsimplantate werden zusätzlich zu den dauerhaft im Kiefer verbleibenden Implantaten eingepflanzt. Die Implantierung der vorübergehenden Implantate wird innerhalb des eigentlichen chirurgischen Eingriffes zur permanenten Implantierung gleichzeitig mit dem Einsatz der verbleibenden Implantate vorgenommen und erfordert nur ein Minimum mehr an Zeit. Ein weiterer Vorteil besteht darin, dass die Originalprothese des Patienten als vorübergehender herausnehmbarer Zahnersatz während der Integrationsphase dienen kann.

SCHLÜSSELWÖRTER: Übergangsprothese, Gewebserhaltung, unmittelbar erfolgende Belastung

AUTOR(ES): David Leshem MD*, Ziv Mazor DMD**, Roy Leshem DMD***, Daren Rosen DDS****. *Jefe de Residentes, Departamento de Cirugía Plástica y Reconstructiva, Centro Médico Sourasky, Tel Aviv, Israel. **Práctica Privada, Ra'anana, Israel. ***Práctica Privada, Herzlia, Israel. ****Cirujano Principal, Unidad de Cirugía Oral y Maxilofacial, Centro Médico Sapir, Kfar Saba; Práctica Privada, Ra'anana, Israel. Correspondencia a: Roy Leshem, DMD, P.O. Box 2022, Herzlia, Israel. Teléfono: +072-9-955 8486, Fax: +972-9-958 6803. Correo electrónico: leshem_y@netvision.net.il Una técnica simple para la fabricación de prótesis removibles interinas inmediatas apoyada en implantes transitorios

ABSTRACTO: El período de curación entre la colocación del implante y el contacto es a menudo un desafío para el paciente y el cirujano. El uso de una prótesis dental removable no se recomienda durante un período de varios días hasta 2 semanas para evitar la presión indebida que se ejerce en el nuevo implante y en los tejidos suaves que lo rodean. Sin embargo, los pacientes a menudo se sienten incómodos sin las dentaduras, inclusive durante un breve período de tiempo, ya que se comprometen su apariencia y su dieta. Se creó una técnica simple para superar estos obstáculos. Esta técnica permite al cirujano colocar una prótesis inmediata apoyada por implantes, basada en dos implantes transitorios, además de los implantes colocados para la restauración final. Esta técnica se usa en la etapa quirúrgica simultáneamente con la colocación de los implantes permanentes. Requiere una cantidad mínima de tiempo adicional y se beneficia de la prótesis original del paciente como una restauración removable interina durante el período de integración.

PALABRAS CLAVES: prótesis interina, conservación del tejido, carga inmediata